

# AIS PennHIP

(877) 727-6800 www.antechimagingervices.com

Owner's Copy

## PennHIP Report

Referring Veterinarian: Dr Steve Jacobs	Clinic Name: SportsVet Animal Medical Center
Email: sportsvetamc@gmail.com	Clinic Address: 1105 N. Dunlap Savoy, IL 61874
	Phone:
	Fax:

## Patient Information

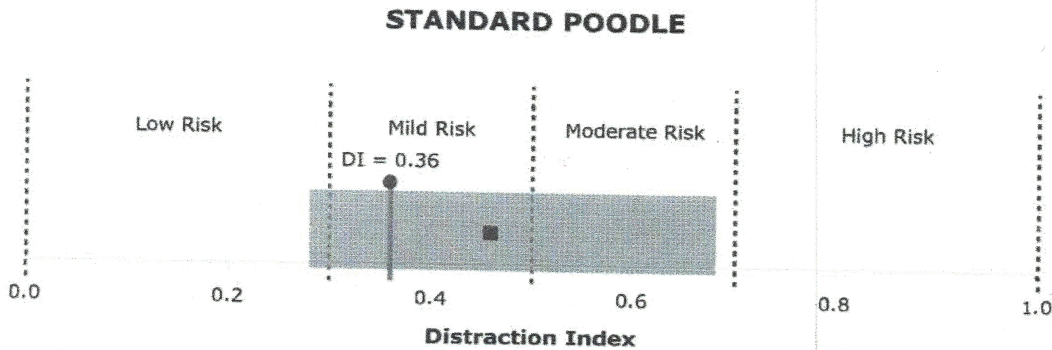
Client: PROBST, KRISTINE	Tattoo Num:
Patient Name: DUNBAR'S TITAN	Patient ID: 44035
Reg. Name: DUNBAR'S TITAN	Registration Num: PR24901305
PennHIP Num: 194981	Microchip Num:
Species: Canine	Breed: STANDARD POODLE
Date of Birth: 04 Nov 2021	Age: 23 months
Sex: Male	Weight: 58.4 lbs/26.5 kgs
Date of Study: 23 Oct 2023	Date Submitted: 23 Oct 2023
Date of Report: 24 Oct 2023	

## Findings

Distraction Index (DI): Right DI = 0.36, Left DI = 0.35.  
 Osteoarthritis (OA): **No radiographic evidence of OA for either hip.**  
 Cavitation/Other Findings: No cavitation present.

## Interpretation

Distraction Index (DI): The laxity ranking is based on the hip with the greater laxity (larger DI). In this case the DI used is 0.36.  
 OA Risk Category: The DI is between 0.31 and 0.49. This patient is at mild risk for hip OA.  
 Distraction Index Chart:



**BREED STATISTICS:** This interpretation is based on a cross-section of 6335 canine patients of the STANDARD POODLE breed in the AIS PennHIP database. The gray strip represents the central 90% range of DIs (0.28 - 0.68) for the breed. The breed average DI is 0.46 (solid square). The patient DI is the solid circle (0.36).

**SUMMARY:** The degree of laxity (DI = 0.36) falls within the central 90% range of DIs for the breed. This amount of hip laxity places the hip at a mild risk to develop hip OA. **No radiographic evidence of OA for either hip.**

**Orthopedic Foundation for Animals**  
**Preliminary Elbow Dysplasia Evaluation Report**



A Not-for-Profit  
Organization

**DUNBAR'S TITAN**  
*registered name*

**PR24901305**  
*registration no.*

**POODLE, STANDARD**  
*breed*

**M**  
*sex*

*film/test/lab #*

**11/04/2021**  
*date of birth*

*tattoo/microchip/DNA profile*

**23**  
*age at evaluation in months*

**2497954**  
*application number*

**10/27/2023**  
*date of report*

**Owner**

**KRISTINE PROBST**  
12524 N 300TH ST  
WHEELER IL 62479

**Veterinarian**

**SPORTSVET ANIMAL MEDICAL CENTER**  
1105 N DUNLAP AVE  
SAVOY IL 61874

**Preliminary Elbow Dysplasia Evaluation Report**

**ELBOW JOINTS -- FLEXED LATERAL VIEW**

negative for elbow dysplasia      L       R

**ELBOW DYSPLASIA**

GRADE I                      L \_\_\_\_\_ R \_\_\_\_\_  
GRADE II                     L \_\_\_\_\_ R \_\_\_\_\_  
GRADE III                    L \_\_\_\_\_ R \_\_\_\_\_

**RADIOGRAPHIC FINDINGS**

degenerative joint disease (DJD)      L \_\_\_\_\_ R \_\_\_\_\_  
united anconeal process (UAP)        L \_\_\_\_\_ R \_\_\_\_\_  
fragmented coronoid process (FCP)    L \_\_\_\_\_ R \_\_\_\_\_  
osteochondrosis                        L \_\_\_\_\_ R \_\_\_\_\_

*G.G. Keller DVM*

G.G. KELLER, DVM, MS, DACVR  
CHIEF OF VETERINARY SERVICES