AIS PennHIP

(877) 727-6800 www.antechimagingservices.com

Owner's Copy

PennHIP Report

Referring Veterinarian: Dr Steve Jacobs

Email: sportsvetamc@gmail.com

Clinic Name: SportsVet Animal Medical Center

Clinic Address: 1105 N. Dunlap
Savoy, IL 61874

Phone:

Fax:

Patient Information

Client: PROBST, KRISTINE

Patient Name: BENJAMIN HARRISON OF IGPK

Reg. Name: BENJAMIN HARRISON OF IGPK

PennHIP Num: 194982

Species: Canine

Date of Birth: 27 Jun 2022

Sex: Male

Date of Study: 23 Oct 2023

Date of Report: 24 Oct 2023

Tattoo Num:

Patient ID: 44562

Registration Num: PR26028604

Microchip Num: 900235000041176

Breed: STANDARD POODLE

Age: 16 months

Weight: 38.1 lbs/17.3 kgs

Date Submitted: 23 Oct 2023

Findings

Distraction Index (DI): Right DI = 0.43, Left DI = 0.46.

Osteoarthritis (OA): **No radiographic evidence of OA for either hip.**

Cavitation/Other Findings: No cavitation present.

Interpretation

Distraction Index (DI): The laxity ranking is based on the hip with the greater laxity (larger DI). In this case the DI used is 0.46.

OA Risk Category: The DI is between 0.31 and 0.49. This patient is at mild risk for hip OA.

Distraction Index Chart:

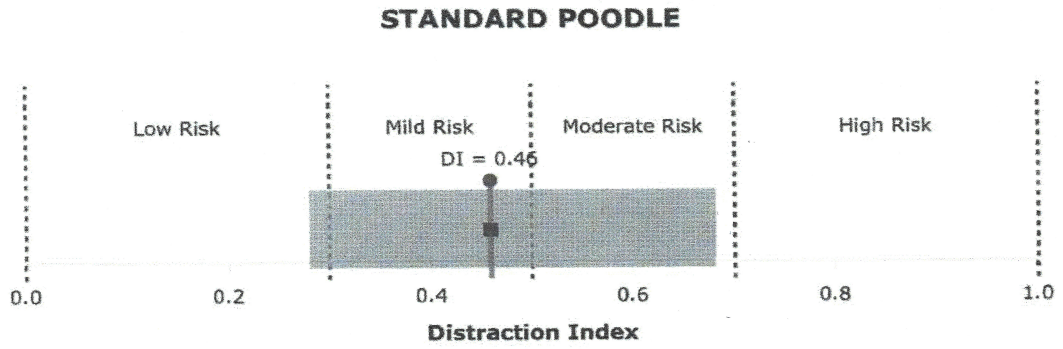

BREED STATISTICS: This interpretation is based on a cross-section of 6335 canine patients of the STANDARD POODLE breed in the AIS PennHIP database. The gray strip represents the central 90% range of DIs (0.28 - 0.68) for the breed. The breed average DI is 0.46 (solid square). The patient DI is the solid circle (0.46).

SUMMARY: The degree of laxity (DI = 0.46) falls within the central 90% range of DIs for the breed. This amount of hip laxity places the hip at a mild risk to develop hip OA. **No radiographic evidence of OA for either hip.**

Orthopedic Foundation for Animals

Preliminary Elbow Dysplasia Evaluation Report

A Not-for-Profit Organization

BENJAMIN HARRISON OF IGPK
registered name

POODLE, MINIATURE
breed

film/test/lab #

900235000041176
tattoo/microchip/DNA profile

2497435
application number

10/26/2023
date of report

PR26028604
registration no.

M
sex

06/27/2022
date of birth

15
age at evaluation in months

Owner

KRISTINE PROBST
12524 N 300TH ST
WHEELER IL 62479

Veterinarian

SPORTSVET ANIMAL MEDICAL CENTER
1105 N DUNLAP AVE
SAVOY IL 61874

Preliminary Elbow Dysplasia Evaluation Report

ELBOW JOINTS -- FLEXED LATERAL VIEW

√ negative for elbow dysplasia	L √	R √

ELBOW DYSPLASIA

GRADE I	L	R
GRADE II	L	R
GRADE III	L	R

RADIOGRAPHIC FINDINGS

degenerative joint disease (DJD)	L	R
ununited anconeal process (UAP)	L	R
fragmented coronoid process (FCP)	L	R
osteochondrosis	L	R

G.G. Keller DVM

G.G. KELLER, DVM, MS, DACVR
CHIEF OF VETERINARY SERVICES

2300 E Nifong Blvd | Columbia MO 65201 | Phone (573) 442-0418 | Fax (573) 875-5073 | ofa@offa.org | www.ofa.org